



PATIENT

Lulu Sciuèche

SPECIES

Canine

BREED

Cavapoo

SEX

FS

AGE

8yr

WEIGHT

26.6lb

PRESENTING CLINICAL SIGNS

- New heart murmur, cardiomegaly (enlarged LA0 on thoracic rads)
- no C.S
- Abnormal PE/Chem/CBC/UA Results: BW WNL,

ULTRASONOGRAPHIC EXAMINATION OF THE HEART

CANINE CARDIAC PARAMETERS	MR VMAX (m/s)	TR VMAX (m/s)	LA/AO M-mode	LA/AO (Heart Base; Swe)	FS (%)	EF (%)	EPSS (cm)
NORMAL PARAMETER	4.5-5.5	<2.7	1.3	Up to 1.6	28-40	40-100	<0.6
PATIENT	--	--	--	1.25	49	82	0.3
CANINE CARDIAC PARAMETERS	HR (BPM)	AV VMAX (m/s)	PV MAX (m/s)	BODY WEIGHT	LAD LA MAX 4 Chamber	LVIDd Avg; 2D and m-mode short axis (cm)	LVIDs Avg; 2D and m-mode short axis (cm)
NORMAL PARAMETER	50-100	0.7-1.7	0.7-1.6				
PATIENT	NM	1.6	1.2	26.6lb	2.9	3.2	---

INTERPRETED BY

R. McKenzie Daniel, DVM, DABVP (Canine and Feline)

IMAGING PERFORMED BY

Rebecca Hamilton

HOSPITAL NAME

Packanack Animal Hospital

REFERRING VET

Dr Mahoney

INVOICE 23936

DATE
02*19*2026

Cardiac Presentation

The echocardiogram in this patient demonstrated normal left atrial size based on 2 different LA measurement methods. Chamber volumes and echogenicity were normal. The cranial and caudal mitral valve leaflets presented vegetative thickening consistent with mild endocardiosis. Doppler indicated mild eccentric insufficiency. The left ventricle presented thicknesses with linear contour and was not dilated nor restricted. The myocardium presented normal echogenicity without subjective evidence of significant fibrotic or ischemic disease. Contractility of the ventricular walls was adequate and in normal range for this patient evidenced by the fractional shortening measurement and subjective evaluation of the different regions of the myocardium. The left ventricular outflow tract demonstrated normal laminar flow and subjective structural integrity. The right atrium and auricle revealed normal size, structure and content. No evidence of masses was noted or chamber overload. Tricuspid valvular assessment demonstrated adequate linear morphology. The right ventricle was of normal size (1/3 diameter of LV), chordae structure, myocardial echogenicity and thickness. Pulmonic tract assessment revealed normal valve structure, laminar flow, and diameter (approx.1:1 pa/ao ratio). No visible pericardial or free pleura fluid was noted. No echographically detectable evidence of infiltrative disease was visible. The cranial mediastinum and pericardial regions were free of masses in the visible window.

ULTRASONOGRAPHIC FINDINGS

Primary

- Chronic mitral valve disease (B1)



PATIENT

Lulu Sciueche

SPECIES

Canine

BREED

Cavapoo

SEX

FS

AGE

8yr

WEIGHT

26.6lb

INTERPRETED BY

R. McKenzie Daniel,
DVM, DABVP
(Canine and Feline)

IMAGING PERFORMED BY

Rebecca Hamilton

HOSPITAL NAME

Packanack Animal
Hospital

REFERRING VET

Dr Mahoney

INVOICE

23936

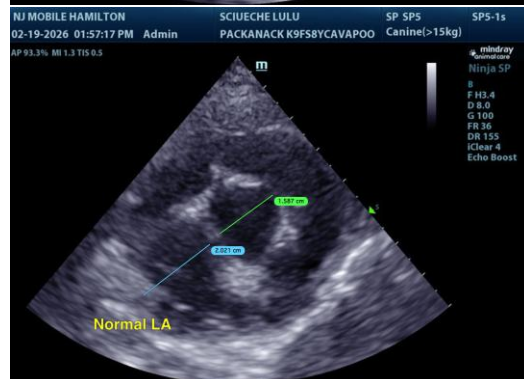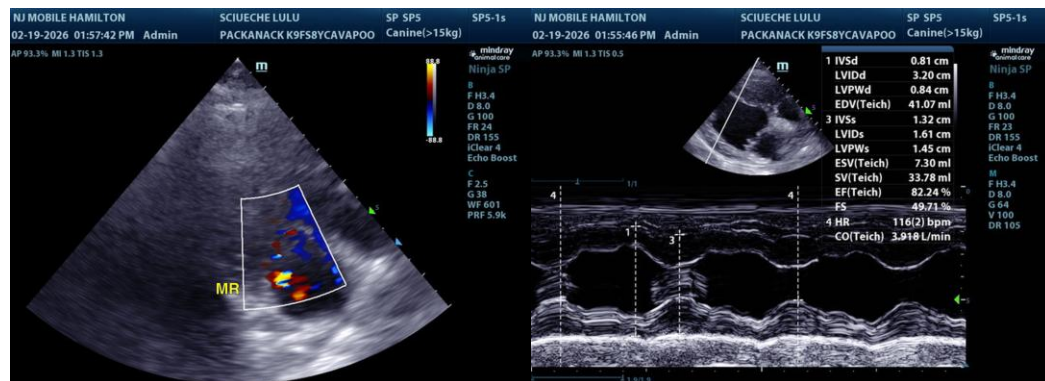
DATE
02*19*2026

INTERPRETATION OF THE FINDINGS & FURTHER RECOMMENDATIONS

The cause of the murmur is subjective mild chronic degenerative valvular changes with secondary MR. No evidence of additional issues such as DCM criteria, LV systolic dysfunction or clinical pulmonary hypertension. The lack of left atrial enlargement implies that the risk of complication secondary to mitral valve insufficiency is relatively low at this time and, without current clinical signs, indicates that medical therapy is not required at this stage.

Prognosis at this stage is variable and serial sonographic monitoring is recommended with a recheck echocardiogram in 6 months, sooner if clinical signs suggestive of heart disease develop.

No anesthetic contraindications. Suggested anesthetic protocol may include opioid or Benzodiazepine pre-med, induction with Propofol or Alfaxalone, and appropriate gas anesthesia with avoidance of alpha 2 agonists.



The information and recommendations provided are based on the images presented by the referring veterinarian/sonographer. No evaluation can be communicated regarding pathology that was not visible in the image/video clips provided.

Thank you for this referral. If the clinical or image interpretation does not parallel your findings or if I can be of any further assistance, please contact me.

R. McKenzie Daniel, DVM, DABVP (Canine/Feline Practice)
info@sonopath.com



PATIENT

Lulu Sciueche

SPECIES

Canine

BREED

Cavapoo

SEX

FS

AGE

8yr

WEIGHT

26.6lb

INTERPRETED BY

R. McKenzie Daniel,
DVM, DABVP
(Canine and Feline)

IMAGING PERFORMED BY

Rebecca Hamilton

HOSPITAL NAME

Packanack Animal
Hospital

REFERRING VET

Dr Mahoney

INVOICE 23936

DATE
02*19*2026